23 STT Arthrodesis

[AU1]

H. Kirk Watson, Jonathan R. Sorelle, Ronit Wollstein, and E. Aron L. Haass

INDICATIONS

Triscaphe/STT Arthrodesis

[AU2,3,4] I (H.K.W.) developed triscaphe/scaphotrapeziotrapezoid (STT) arthrodesis nearly 40 years ago as a management technique for many of the problems involving the scaphoid. The scaphoid is unique in many ways among all of the human skeletal components. It is almost entirely covered by articular cartilage. Blood supply to the bone is a difficult problem, so much so that this is the poorest healing bone in the body, after fracture. The motion demands on the scaphoid are not easily achieved because it crosses both carpal rows. The bone must flex and get out of the way in radial deviation. Along with the lunate, it must carry 100% of the heavy loads transmitted into the radius. The scaphoid is probably protected from avascular necrosis (Preiser disease) because the proximal pole can escape the loads coming through the capitate. Scaphoid stability is primarily dependent on the most commonly damaged ligament in the wrist, the scapholunate interosseous ligament system. Close to 25% of adults normally demonstrate a positive scaphoid shift test associated with some tearing of this ligament (1). The main thrust of all restabilization procedures is to prevent the proximal pole of the scaphoid from escaping from beneath the capitate under load.

Fusing the scaphoid to the lunate provides a long banana-shaped bone with insufficient bone stock to carry the flexing loads. Secondly, there is often a ridge on the articular surface of the radius between the scaphoid fossa and the lunate fossa that the fused unit cannot navigate. Thirdly, the amount of bone between the two is small and technically achieving fusion is very difficult.

The scaphoid can be controlled by fusing its distal pole to the trapezium and trapezoid. Said fusion also allows for an increased blood supply into the scaphoid cancellous bone. Fusing to the trapezium-trapezoid allows motion between the capitate and scaphoid and places responsibility on the capitate-trapezoid ligaments, which are capable of taking such loads. Fusing the scaphoid-trapezium-trapezoid joint allows transfer of loads from the hand through the scaphoid to the radius, circumventing the lunate. This is an ideal treatment for Kienböck disease (2–5).

We have previously described a radiographic technique that we consider one of the most efficient ways to image the STT joint for both preoperative evaluation of STT pathology, as well as to verify successful postoperative fusion after STT arthrodesis. The wrist is placed in 30 degrees of ulnar deviation so that the thumb is extended fully and in a straight line with the forearm. The thumb pulp is facing the cassette and the angle between the straight line of the thumb and forearm and the cassette
[AU5] is about 30 degrees. The central ray in this view is directed at the carpometacarpal (CMC) joint. With this technique, we can outline and isolate the trapezoid joint with the least bony overlap (6).

[AU6] We have published a follow-up of 800 STT fusions. The following is a breakdown of STT fusions by diagnosis: rotary subluxation of the scaphoid (RSS) 49%, Kienböck disease 13%, degenerative arthritis 12%, static rotary subluxation 11%, midcarpal instability 6%, nonunion of the scaphoid 3.5%, early scapholunate advanced collapse (SLAC) 1.8% persistent symptomatic predynamic RSS with instability 1.8%, and 0.4% for the remaining diagnosis including avascular necrosis of the scaphoid, nonunion scapholunate arthrodesis, symptomatic congenital synchondrosis of the triscaphe joint, and nonunion scaphoid with detached proximal pole (7–10).

Utilizing the techniques described herein, the nonunion rate is low, and immobilization time is generally 6 to 7 weeks. After fusion, the scaphoid is held firmly beneath the capitate and power use

of the wrist is in a normal range. Anecdotally, a professional athlete led the National Basketball Association (NBA) in scoring a year after his STT fusion on his shooting wrist. An orthopaedic surgeon from California won his class in the world wrestling championship in Bulgaria. A woman won the northeastern Induro motorcycle championship a year after her STT limited wrist arthrodesis.

CONTRAINDICATIONS

The main contraindication for triscaphe arthrodesis is degenerative changes of the radioscaphoid joint (11,12). If the destruction is restricted to the central portion of the scaphoid in a professional athlete who is highly paid, but for a limited number of years, then an STT arthrodesis may be indicated. This recognizes that as and when SLAC wrist becomes a problem, the STT joint can be osteotomized, the scaphoid removed, and a SLAC reconstruction performed (13). Severe destruction of the radial scaphoid joint or stage II SLAC where the capitate–lunate joint is destroyed are contraindications to an STT fusion and SLAC reconstruction is the preferred approach. A relative contraindication is degenerative arthritis of the STT joint in an elderly person or a person with limited load capacity for other reasons. In this case, the problem can be solved with carpectomy of the trapezium and a properly performed tendon arthroplasty. We mobilize our tendon arthroplasties in 2.5 half weeks and there is considerably less morbidity than 6 to 7 weeks in a cast, some of it long arm and bone graft of an STT fusion.

TECHNIQUE

- Approach the triscaphe joint through a 4-cm transverse dorsal wrist incision just distal to the radial styloid (Fig. 23-1). Use the spreading technique to preserve dorsal veins and branches of the superficial branch of the radial nerve.
- Open the sheath of the extensor pollicis longus tendon and retract the tendon radially.
- Make a transverse incision in the dorsal capsule and inspect the radioscaphoid joint. If significant degenerative disease is found, despite the absence of radiographic evidence preoperatively, our procedure of choice is SLAC reconstruction rather than triscaphe arthrodesis. If the radioscaphoid joint is intact, expose the radial styloid through an incision in the capsule overlying the radial styloid–scaphoid junction, and remove the distal 5 mm of the styloid with a rongeur, sloping volarly from distal to proximal.
- Approach the triscaphe joint through a transverse capsular incision between the extensor carpi radialis longus and brevis tendons.
- Cut back the nonarticular portion of the trapezium and trapezoid dorsal to the articular scaphoid trapezium–trapezoid joint back to a cancellous surface (Fig. 23-2, upper left). This nonarticular

FIGURE 23-1

This is our typical preoperative marking for scaphotrapeziotrapezoid (STT) fusion and distal radius bone graft. [AU11]

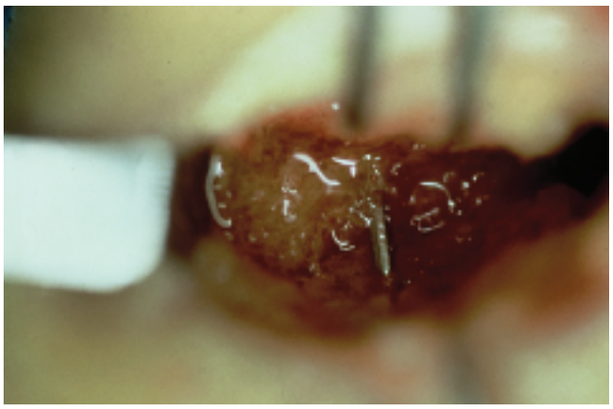

FIGURE 23-2

A: Place a spacer between the scaphoid and trapezoid while the pins are run to prevent approximation of bones and loss of scaphoid flexion. **B:** Volar counter pressure on the scaphoid prevents hyperflexion and maintains the scaphoid within the set parameters as the pins are set. **C,D:** Typical approach to harvesting a distal radius bone graft.

portion part of the fusion site will approximately double the exposed cancellous bone surface of the trapezium and trapezoid.

- Cut back the distal articular surface of the scaphoid to a cancellous convexity.
- With traction on the hand, use a small angled curette to remove the articular cartilage between the trapezium and trapezoid from volar to dorsal in the proximal half of this articulation. This provides a place for one cup of a dental rongeur, making the removal of the articular cartilage and subchondral bone of the trapezium and trapezoid easier to accomplish. This portion of the technique is particularly important in cases of degenerative arthritis. The sclerotic subchondral bone is very hard to access, unless one blade of the dental rongeur can be placed between the trapezium and trapezoid. It is important that not only the cartilage and subchondral bone be removed, but that the bone be cut back to good cancellous bone. This is especially true in longstanding degenerative arthritis, where the cancellous bone immediately beneath the hard subchondral bone may be of poor quality. When dealing with a nonunion of an STT fusion, we often make a cancellous groove running volar to dorsal in the midportion of the distal scaphoid to further access the better cancellous bone.
- At this point, pay direct attention to the radius where a transverse incision 1 inch to 1.5 inches proximal to the wrist incision on the dorsal radial aspect of the radius.
- Dissect down to the artery that lies on the periosteum between the abductor pollicis longus and extensor pollicis brevis tunnel and the extensor carpi radialis longus.
- Make a longitudinal incision along this artery, followed by subperiosteal dissection exposing the dorsal and radial aspect of the radius.
- Remove a teardrop-shaped cortical window with the apex of the teardrop facing proximally (Fig. 23-3) (Fig. 23-4 C,D). This produces a stress riser that is aimed up the longitudinal axis of the radius, rather than a stress riser that might run transversely in case of injury loads. The teardrop is a 1.5 cm wide by 2 to 2.5 cm long in most adults.
- Remove the cortical window and then use a curette to remove cancellous bone.
- Replace the cortical window and enclose the periosteum tunnels to allow the first and second compartments to close over the window.
- Direct attention back to the STT joint where two 0.045 pins are preset in the trapezoid determining their direct alignment into the scaphoid. The more radial of the two pins is left protruding from the trapezoid and this small segment of pin will stabilize the spacer during carpal positioning (Fig. 23-4). One of the basic rules of limited wrist arthrodeses is that the finished fused unit has the same external dimensions as the normal wrist. This principle avoids overloading other joints. This means that a 3- to 4-mm space will probably be necessary between the trapezoid and the scaphoid. This is usually achieved with a handle of a small rake or similar spacer (Fig. 23-5). Achieve carpal alignment by dorsiflexing the wrist 45 degrees and fully radially

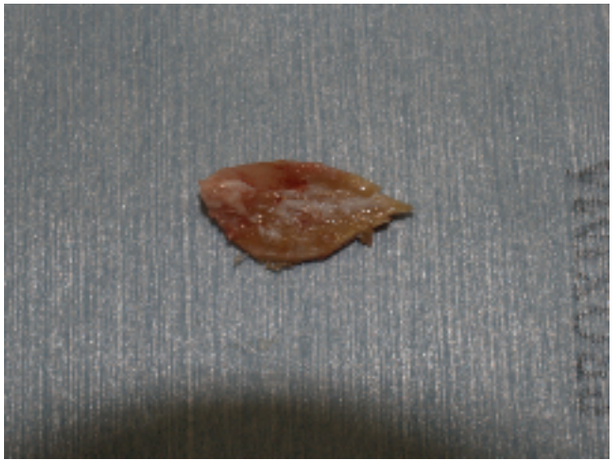

FIGURE 23-3

The teardrop-shaped window of cortical bone taken from the distal radius.

deviating the wrist. This drives the scaphoid into more flexion than normal with the spacer in place. Placing the thumb on the volar tuberosity of the scaphoid prevents overflexion of the scaphoid, maintaining it within these constraints (Fig. 23-4 B). No visual guides are necessary with this positioning (Fig. 23-6).

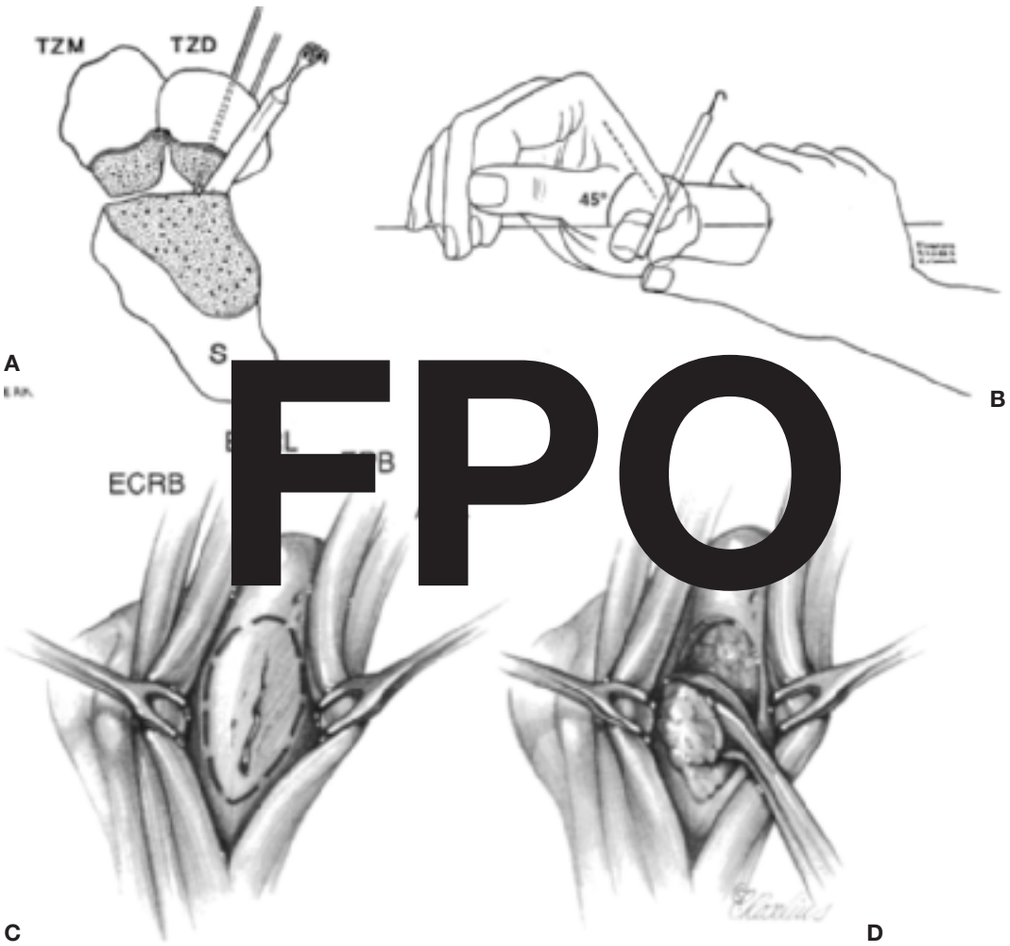

FIGURE 23-4

The pin is surrounded by cancellous bone filling the interfusion spaces.

FIGURE 23-5

An intraoperative photograph showing the placement of the spacer and preset pins.

- Drive the pin alongside this spacer into the scaphoid and then remove the spacer and run the other pin into the scaphoid. It is ideal if the pins can run through the scaphoid to its volar–ulnar cortex without protruding through the scaphoid. Under no circumstances should the pins be driven into the radius. By not having pins crossing into the radius, any motion can occur at the radius–scaphoid joint without unduly loading the fusion site.
- Pack the cancellous bone between the trapezium and trapezoid and between the scaphoid and this bone combination and dorsally against what was the nonarticular portion of the trapezium–trapezoid until the bone grafting is complete.
- Cut off the pins below skin level (Fig. 23-7).

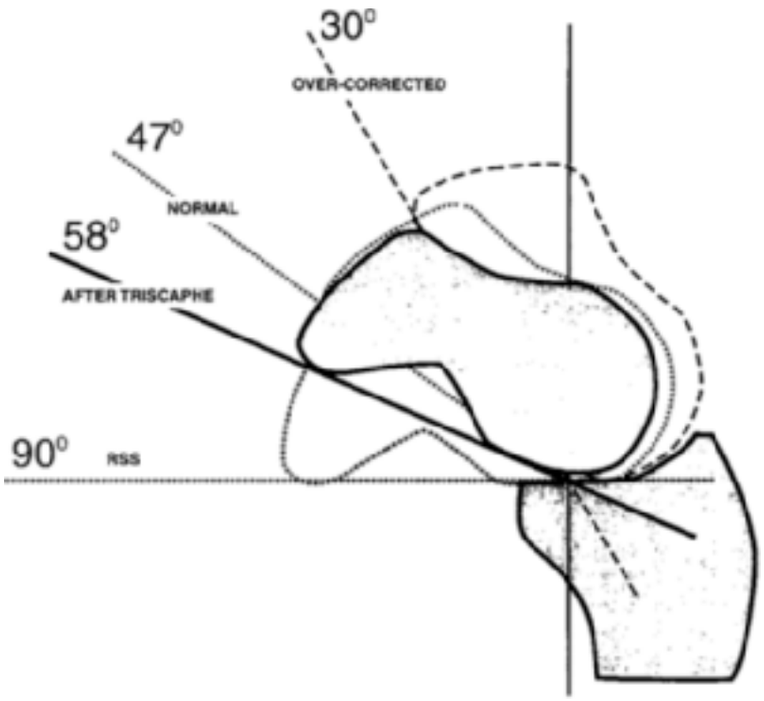

FIGURE 23-6

A diagram of the correct angle of the scaphoid after scaphotrapeziotrapezoid (STT) fusion. This increased scaphoid flexion is necessary for postoperative range of motion and prevention of subsequent degenerative arthritis.

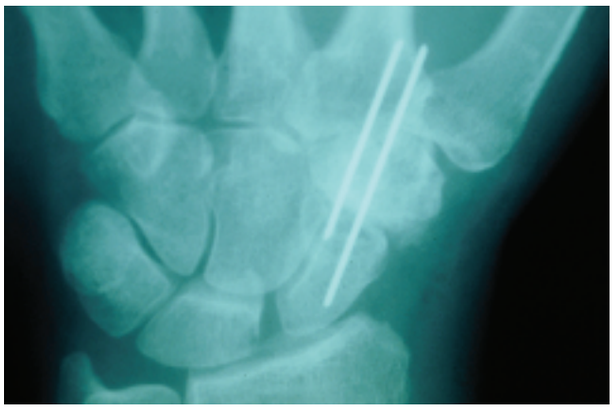

FIGURE 23-7

This postoperative film demonstrates the pins running through the trapezoid into the scaphoid. No pins should reach the radius or the scaphoradius joint.

- Close the wound with a 4.0 subcuticular suture and bulk dressing, and apply a long arm casting splint. It should be noted here that very serious complications can be avoided by having no tight wraps of any dressing around the forearm that will produce edema in the hand. Serious Volkman-like changes to the intrinsic muscles are possible with a forearm constrictive dressing.

POSTOPERATIVE MANAGEMENT

At 48 hours postsurgery, remove the splint and operative dressing, and apply a long arm cast. We term this the "Groucho Marx" cast because the thumb and index and middle proximal phalanges are included in the cast in a flexed position. Flexing the MP joint stabilizes the proximal phalanx and [AU7] helps to hold the index and middle metacarpals securely, thus immobilizing the distal aspect of the STT fusion. The long arm cast is maintained for 3 weeks at which point it is replaced by a short arm gauntlet cast. It is our position that by 3 weeks reasonable adhesiveness exists in the fusion site and it needs only to be protected adequately for an additional 3 weeks from any significant loads. The pins, of course, are still in place.

At 6 weeks, remove the long arm cast. Obtain an x-ray study and, with any insecurity about the appearance at the fusion site, then an additional week or 10 days might be warranted in a short arm gauntlet cast. Otherwise, at 6 weeks, with a small amount of 1% Xylocaine over the pins, remove them in the office with very tiny transverse incisions. It is important when using a needle holder to remove the pins not to hold the end of the pin with the needle holder in longitudinal alignment with the pin. The needle holder should be at 90 degrees to the long axis of the pin and then by rocking the needle holder back and forth over a short arc with gentle pressure on the needle holder the pin can be removed. If the needle holder is in line with the longitudinal axis of the pin, then each time it slips off the pin, it will drive the pin ahead of it and eventually bury the pin in bone requiring a surgical approach.

Following pin removal, full unrestricted activity is allowed and encouraged by therapy. It should be noted that around 3 months from the surgery or a month or two after pin removal is usually the most discouraging time for patients. They are healed. They are mobilizing, but the wrist is adapting to the new motion planes required of an STT fusion and the wrist is often symptomatic and lacks the power the patient has been led to expect. Following the 3-month postoperative period, there is a steady ratcheting tolerance and range of motion.

PEARLS AND PITFALLS

- Must have good or usable scaphoradius joint
- Increase the cancellous surface by removing the dorsal nonarticular surface from the trapezoid and trapezium.
- Position the scaphoid in more flexion than the normal wrist.

- Ensuring Kirschner wire placement does not violate the radioscaphoid joint.
- Remove the tip of the radial styloid.

COMPLICATIONS

In early cases, a significant postoperative incidence of radial styloid symptoms occurred. The stabilized scaphoid is not a congruous fit for the long fossa of the radius. Among these early cases, approximately 20% required a subsequent styloidectomy. Since 1987, radial styloidectomy has been routinely performed as part of the triscaphe arthrodesis procedure (15).

Nonunion has been uncommon, with a rate of 1% to 3%, depending on the indication for limited wrist arthrodesis (16). We believe that this rate of nonunion is kept low by the broad cancellous surface created at the time of articular resection and the large volume of cancellous graft used in performing the fusion. Infection, hematoma, and transient neurapraxias have been exceedingly rare in our experience and are avoidable. One patient required drainage and antibiotics for a postoperative wound infection. Fifteen patients (2%) were treated for postoperative reflex sympathetic dystrophy with a Dystrophile (stress-loading) regimen consisting of compression (scrubbing tasks) and traction (carrying weights) (17).

Although degenerative change at the radioscaphoid joint (SLAC wrist) occurred in 1.5% of patients following triscaphe arthrodesis, radiolunate degenerative change was not observed in any cases (18,19). These 1.5% of triscaphe arthrodeses required conversion to SLAC reconstruction. This entailed osteotomy through the triscaphe fusion, carpectomy of the scaphoid, and arthrodesis of the capitate, lunate, hamate, and triquetrum. Pain was the usual indication. Radioscaphoid degenerative joint disease often occurred in patients in whom some degenerative joint disease was present at the time of the original surgery.

In several cases, patients were willing to accept expected future degenerative arthritis in exchange for shorter term, full-power, asymptomatic function with increased range of motion. This trade-off allowed them to finish out careers during their exceptional remuneration years. Several professional athletes and one world-class wrestler demonstrated eburnated bone with complete cartilage loss involving the proximal scaphoid pole. This approach is successful because the central portion of the scaphoid pole is destroyed while the central area of the scaphoid fossa of the radius is preserved. Triscaphe arthrodesis places the damaged proximal pole back in the center of the preserved cartilage of the scaphoid fossa.

RESULTS

Triscaphe arthrodesis has been an extremely reliable procedure with relatively few complications. The [AU8] senior author has performed more than 900 of these procedures. The mean postoperative immobilization, used as a measure of time to bony fusion, was 48 days (range from 30 to 294 days). The overall range of motion was 70% to 80% of the nonoperated side and strength was 69% to 89%. Of the patients, 88% returned to previous employment. Arthritis developed in 1.8% of the patients (Table 23-1).

[AU12] **TABLE 23-1. Objective Postoperative Results of Scaphotrapeziotrapezoid (STT) Arthrodesis Shows Consistent Results when Compared by Diagnosis**

	Range of Motion				
Diagnosis	E/F	R/U	Grip	Key Pinch	Tip Pinch
Dynamic RSS	76/83	65/76	77	91	65
Static RSS	81/83	66/77	78	93	69
Kienbock's	66/69	62/72	68	91	68
STT-DJD	80/85	81/82	77	95	67
Midcarpal instability	79/77	62/76	70	83	58
Nonunion of scaphoid	68/75	59/66	73	88	60
Early SLAC	70/82	60/83	79	90	72
Total	79/74	71/78	77	89	69

[AU13] RSS, rotary subluxation of the scaphoid; SLAC, scapholunated advanced collapse; STT-DJD, scaphoidtrapeziumtrapezoid-_____. (From Watson HK, Wollstein R, Joseph E, et al. Scaphotrapeziotrapezoid arthrodesis: a follow-up study. *J Hand Surg* 28A(3):397–404, 2003, with permission.)

REFERENCES

1. Watson HK, Weinzweig J, Zeppieri J. The natural progression of scaphoid instability. *Hand Clinics* 1997;13(1):39–50, 1997.
2. Watson HK, Lionelli GT. Scaphoid-trapezium-trapezoid/triscaphe fusion for Kienbock's disease. *Atlas of Hand Clinics* 4 (2):119–133, 1999.
3. Watson HK, Ryu J, DiBella A. An approach to Kienbock's disease: triscaphe arthrodesis. *J Hand Surg [Am]* 10:179–187, 1985.
4. Watson HK, Fink JA, Monacelli DM. Use of triscaphe fusion in the treatment of Kienbock's disease. *Hand Clin* 9:493–499, 1993.
5. Watson HK, Weinzweig J. Treatment of Kienbock's disease with triscaphe arthrodesis. In: Vastamaki M, Vilkki S, Goransson H, et al., eds. *Proceedings of the 6th Congress of the International Federation of Societies for Surgery of the Hand*. Bologna: Monduzzi Editore, 347–349, 1995.
6. Wollstein R, Wandzy N, Mastella DJ, et al. A radiographic view of the scaphotrapezium-trapezoid joint. *J Hand Surg* 30A(6):1161–1163, 2005.
7. Watson HK, Wollstein R, Joseph E, et al. Scaphotrapeziotrapezoid arthrodesis: a follow-up study. *J Hand Surg* 28A(3):397–404, 2003.
8. Weinzweig J, Watson HK, Herbert TJ, et al. Congenital synchondrosis of the scaphotrapezio-trapezoid joint. *J Hand Surg [Am]* 22:74–77, 1997.
9. Watson HK, Ottoni L, Pitts EC, et al. Rotary subluxation of the scaphoid: A spectrum of instability. *J Hand Surg [Br]* 18:62–64, 1993.
10. Watson HK, Ryu J, Akelman E. Limited triscaphoid intercarpal arthrodesis for rotary subluxation of the scaphoid. *J Bone Joint Surg [Am]* 68:345–349, 1986.
11. Rogers WD, Watson HK. Radial styloid impingement after triscaphe arthrodesis. *J Hand Surg [Am]* 14:297–301, 1989.
12. Trumble T, Bout C, Smith R, et al. Intercarpal arthrodesis for static and dynamic volar intercalated segment instability. *J Hand Surg [Am]* 13:396–402, 1988.
13. Watson HK, Weinzweig J, Ashmead D. Triscaphe arthrodesis. In: Gelberman R, ed. *The Wrist*. Philadelphia: Lippincott Williams, & Wilkins, 205–214, 2002.
14. *The Wrist*, H Kirk Watson, Jeffrey Weinzweig. Lippincott Williams & Wilkins, 2001 page 931–939. [AU9]
15. Rogers WD, Watson HK. Radial styloid impingement after triscaphe arthrodesis. *J Hand Sur* 14:297–301, 1989.
16. Wollstein R, Watson HK. Scaphotrapeziotrapezoid arthrodesis for arthritis. *Hand Clinics* 21(4):539–543, 2005.
17. Watson HK, Carlson L. Treatment of reflex sympathetic dystrophy of the hand with active "stress loading" program. *J Hand Surg [Am]* 12:779–785, 1987.
18. Watson HK, Weinzweig J. *The Wrist* Philadelphia: Lippincott Williams & Wilkins, 931–939, 2001. [AU10]
19. Watson HK, Weinzweig J, Guidera P, et al. One thousand intercarpal arthrodeses. *J Hand Surg [Br]* 24:320–330, 1999.

[AU1]Should STT be spelled out in title?
[AU2]Please confirm HKW is correct here.
[AU3]By virgule construction, do you mean a combination or triscaphe & STT?
[AU4]STT spelled out as meant?
[AU5]CMC spelled out as meant?
[AU6]Do you have a reference for the published follow-up?
[AU7]Please define MP here at first mention.
[AU8]Do you mean Dr. Watson? If so, please inset initials in parenthesis.
[AU9]Is ref 14 an incomplete repeat or reference 13? If so, reference list needs to be renumbered and change made in text.
[AU10]If this is a chapter in the text, please list title.
[AU11]STT spelled out as meant?
[AU12]Delete table head below?
[AU13]Please define the DJD portion of this abbreviation.